

MANAGEMENT OF ENDOCRINE DISEASE

A clinical update on tumor-induced hypoglycemia

Pedro Iglesias and Juan J Díez

Department of Endocrinology, Hospital Ramón y Cajal, Ctra. de Colmenar, Km 9.100, 28034 Madrid, Spain

Correspondence should be addressed to P Iglesias
Email
piglo65@gmail.com

Abstract

Tumor-induced hypoglycemia (TIH) is a rare clinical entity that may occur in patients with diverse kinds of tumor lineages and that may be caused by different mechanisms. These pathogenic mechanisms include the eutopic insulin secretion by a pancreatic islet β -cell tumor, and also the ectopic tumor insulin secretion by non-islet-cell tumor, such as bronchial carcinoids and gastrointestinal stromal tumors. Insulinoma is, by far, the most common tumor associated with clinical and biochemical hypoglycemia. Insulinomas are usually single, small, sporadic, and intrapancreatic benign tumors. Only 5–10% of insulinomas are malignant. Insulinoma may be associated with the multiple endocrine neoplasia type 1 in 4–6% of patients. Medical therapy with diazoxide or somatostatin analogs has been used to control hypoglycemic symptoms in patients with insulinoma, but only surgical excision by enucleation or partial pancreatectomy is curative. Other mechanisms that may, more uncommonly, account for tumor-associated hypoglycemia without excess insulin secretion are the tumor secretion of peptides capable of causing glucose consumption by different mechanisms. These are the cases of tumors producing IGF2 precursors, IGF1, somatostatin, and glucagon-like peptide 1. Tumor autoimmune hypoglycemia occurs due to the production of insulin by tumor cells or insulin receptor autoantibodies. Lastly, massive tumor burden with glucose consumption, massive tumor liver infiltration, and pituitary or adrenal glands destruction by tumor are other mechanisms for TIH in cases of large and aggressive neoplasias.

European Journal of Endocrinology
(2014) **170**, R147–R157

Introduction

Hypoglycemia not associated with diabetes and/or its therapy is an uncommon clinical disorder. In people without diabetes, the diagnosis of hypoglycemia is usually established when venous plasma glucose is <55 mg/dl (3 mmol/l) and supported by the presence of Whipple's triad (symptoms, signs, or both consistent with hypoglycemia, a low plasma glucose concentration, and resolution of those symptoms or signs after raising plasma glucose concentration) (1).

In ill or medicated adults without diabetes, the most common causes of hypoglycemia are drugs other than insulin or insulin secretagogues. Other etiologies are critical illnesses and hormone deficiencies (cortisol and

glucagon). In seemingly well non-diabetic individuals, hypoglycemia is usually associated with endogenous hyperinsulinism due to nesidioblastosis, tumor β -cell disorders, and insulin autoimmune hypoglycemia. On other occasions, the etiology of hypoglycemia in these patients can be accidental, surreptitious, or malicious (1). Lastly, tumor hypersecretion of several factors with hypoglycemic effects have also been documented.

Tumor-induced hypoglycemia (TIH) is a rare clinical type of hypoglycemia that usually appears as a result of insulin hypersecretion by a pancreatic islet β -cell tumor (insulinoma). However, TIH can also be developed by other non-pancreatic tumors (non-islet-cell tumor

hypoglycemia (NICTH)). This review focuses on the most updated and relevant clinical, diagnostic, and therapeutic aspects related to TIH, as well as different clinical situations related to insulinoma, the most common cause of TIH.

Pathophysiology of TIH

Several pathogenetic mechanisms may explain TIH (Table 1 and Fig. 1). The most common cause, although rare, is tumor hyperinsulinism induced by a pancreatic islet β -cell tumor (insulinoma). However, NICTH is nowadays a well-recognized etiology of TIH (2). In this case, the main etiology of hypoglycemia is the release by the tumor of insulin-like growth factor 2 (IGF2) or its high-molecular-weight precursor (big IGF2) (3, 4, 5, 6, 7, 8, 9, 10, 11). Other mechanisms for NICTH are IGF1 tumor

secretion (12), the production of autoantibodies to insulin (13) or its receptor (14), or more rarely, the secretion of glucagon-like peptide 1 (GLP1) (15, 16), and massive tumor burden (17). Lastly, ectopic insulin secretion by a non-islet-cell tumor has also been exceptionally reported (18, 19, 20, 21, 22, 23).

Insulin-secreting tumors

Eutopic tumor insulin secretion: pancreatic islet β -cell tumor (insulinoma)

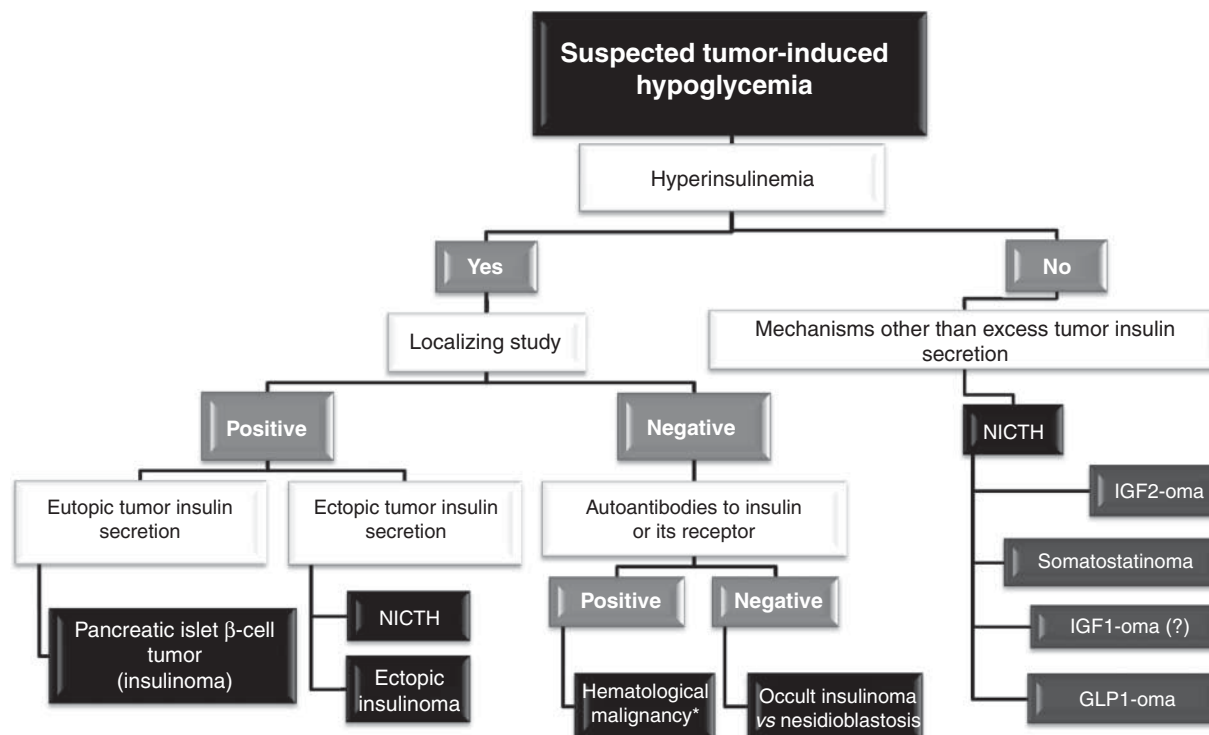
Insulinoma is a rare tumor with an incidence of 0.4/100 000 person-years (four cases per million per year), more frequently observed in the fifth decade of life (median age 47 years, range 8–82 years) and with a slight predominance (~60%) for the female sex (24). This tumor is the most common (~25%) functioning pancreatic neuroendocrine tumor (pNET). Insulinomas are usually single, small (usually <2 cm diameter), well-circumscribed, benign, sporadic, intrapancreatic tumors, and evenly distributed throughout the pancreas (Fig. 2) (24, 25, 26, 27).

Hypoglycemic symptoms secondary to excessive and uncontrolled secretion of insulin by the tumor usually occur in the fasting state (73%); however, they can also be present only in the postprandial state (6%) and in both fasting and postprandial states (21%) (28). Correct diagnosis is often delayed until 2 years from the onset of symptoms due to the fact that, on many occasions, neuropsychiatric or neurologic symptoms are misunderstood (1, 24, 29). Hypoglycemic symptoms can be neurogenic (autonomic) (hunger, sweating, paresthesia, palpitations, diaphoresis, anxiety, and tremor) and neuroglycopenic (confusion, visual disturbances, behavioral changes, epileptic seizures, confusion, and coma) (30). Weight gain and obesity as a consequence of frequent small meals to avoid hypoglycemic symptoms is a well-known clinical sign of insulinoma (31, 32).

Biochemical diagnosis of insulinoma is established when hypoglycemia, supported by the presence of Whipple's triad, is associated with endogenous hyperinsulinism showing the following criteria: fasting plasma glucose concentrations are <55 mg/dl (3.0 mmol/l), plasma insulin concentrations $\geq 3 \mu\text{U/ml}$ (18 pmol/l), plasma C-peptide concentrations $\geq 0.6 \text{ ng/ml}$ (0.2 nmol/l), plasma proinsulin concentrations $\geq 5 \text{ pmol/l}$, plasma β -hydroxybutyrate levels $\leq 2.7 \text{ mmol/l}$, change in blood glucose $\geq 25 \text{ mg/dl}$ (1.4 mmol/l) at 30 min after 1 mg i.v. glucagon, a negative sulfonylurea screen in the plasma

Table 1 Pathogenic mechanisms and types of tumors associated with tumor-induced hypoglycemia.

Insulin-secreting tumors
Eutopic tumor insulin secretion: pancreatic islet β -cell tumor
Insulinoma
Ectopic tumor insulin secretion: non-islet-cell tumors
Bronchial carcinoid
Gastrointestinal stromal tumor
Squamous cell carcinoma of the cervix
Schwannoma
Neurofibrosarcoma
Paranglioma
Small-cell carcinoma of the cervix
Mechanisms other than excess tumor insulin secretion
Tumor IGF2 precursors secretion (big IGF2) 'IGF2-oma'
Leiomyosarcoma
Fibrosarcoma
Adrenal carcinoma
Desmoplastic small round cell tumor
Hemangiopericytoma
Pheochromocytoma
Renal sarcoma
Uterine leiomyoma
Hepatocellular carcinoma
Gastric carcinoma
Tumor somatostatin secretion 'Somatostatinoma'
Pancreatic neuroendocrine tumor
Ovarian neuroendocrine tumor
Tumor IGF1 secretion 'IGF1-oma'
Large-cell carcinoma of the lung
Tumor glucagon-like peptide 1 (GLP1) secretion 'GLP1-oma'
Ovarian neuroendocrine tumor
Pancreatic neuroendocrine tumor
Autoantibodies to insulin or its receptor 'Tumor autoimmune hypoglycemia'
Other tumor-related factors
Massive tumor burden
Massive liver tumor infiltration
Pituitary and/or adrenal glands tumor destruction

**Figure 1**

Diagnostic algorithm for patients with suspected tumor hypoglycemia. *After excluding other non-tumor causes of autoimmune hypoglycemia. NICTH, non-islet-cell tumor hypoglycemia.

and/or urine and no circulating antibodies to insulin (1). When Whipple's triad has not been documented in a patient with suggestive clinical evidence of hypoglycemia or when biochemical study during the hypoglycemia could not be performed, the patient should undergo a supervised 72-h fast test with the aim to reproduce the hypoglycemic episode. Diagnosis of insulinoma must be confirmed by localizing the tumor by conventional imaging, such as computed tomography (CT), magnetic resonance imaging (MRI), and transabdominal ultrasonography. These localizing techniques detect most insulinomas (Fig. 2); however, due to the small size of some tumors, a negative study does not always exclude its presence (1, 33, 34).

Although medical therapy with frequent carbohydrate meals and diazoxide (~200–600 mg/day orally) or somatostatin analogs may control hypoglycemic symptoms in 50–60% of patients, only surgery is curative (26, 29). Therefore, once the tumor has been located, the treatment of choice is surgical excision. The surgical method usually employed (~60%) is enucleation of the tumor, followed by partial pancreatectomy (24). Although the majority of the interventions have been made using open surgery,

laparoscopic surgery is a surgical option in some centers with a morbidity rate comparable with that for the open approach. When the tumor is not found during laparoscopy, laparoscopic ultrasonography seems to be the most efficient tool to localize it and probably to prevent conversion (35, 36). Those tumors located in the body or tail of the pancreas can better benefit from the laparoscopic approach (37). Alternative medical treatment may be necessary for symptomatic patients with unresectable tumors and for those who are not candidates for surgical treatment or refuse surgery (1, 33, 34). The alternative option of endoscopic ultrasonography (EUS) or intraoperative (IO) US-guided ethanol fine-needle injection has recently been reported for the treatment of symptomatic insulinomas requiring extensive resection and for poor surgical candidates (38). Highlights of different special clinical situations related with insulinoma are presented below.

Occult insulinoma ► A small number of insulinomas remain occult after conventional (ultrasonography, CT scan, or MRI) localizing preoperative study (26).

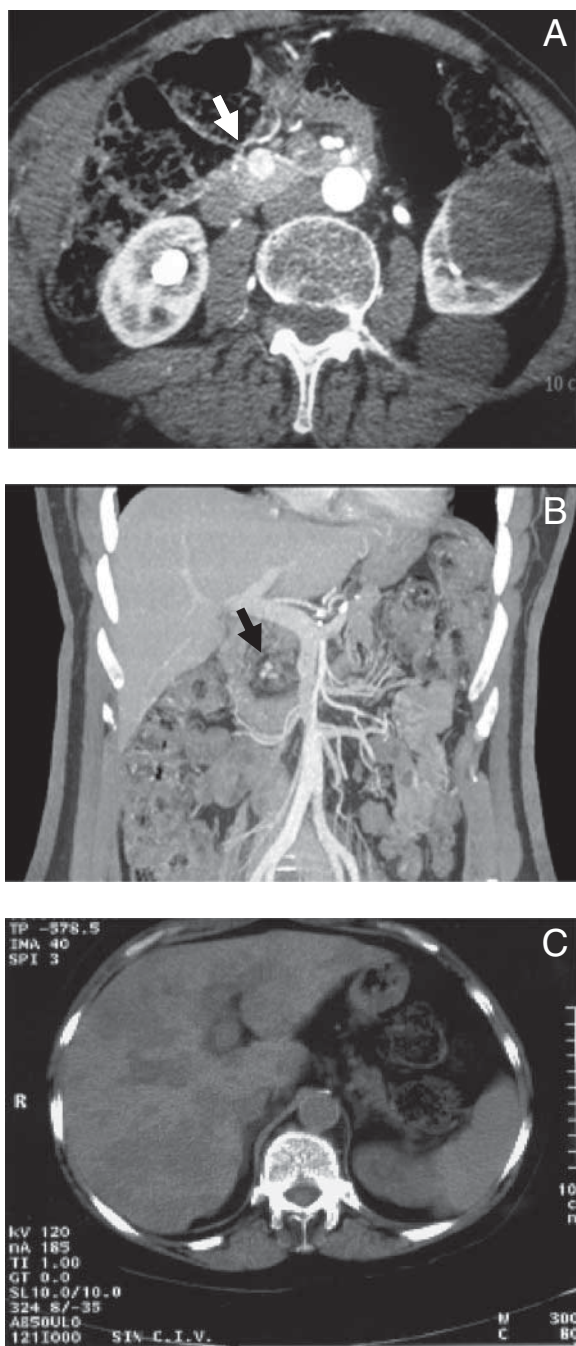


Figure 2

Abdomen CT scan image with i.v. contrast in a woman with a 1.5 cm benign insulinoma (white arrow) located in the head of the pancreas (A). Abdomen CT scan with contrast showing three small images (black arrow) compatible with multiple insulinomas in the head of the pancreas in a female patient (B). CT scan without contrast of the abdomen showing multiple liver metastases in a female patient with malignant insulinoma (C).

In some cases, pancreatic dynamic consecutive enhanced CT scanning may help to localize the tumor (39). Somatostatin receptor scintigraphy detects between 20 and 50% of affected patients with benign insulinomas (34, 40). The abundance of GLP1 receptors (GLP1R) in pancreatic β -cells in insulinomas has led to the development of GLP1R scanning by using GLP1-like radioligands with high binding affinity to GLP1Rs to localize occult insulinomas (41). GLP1R scan with ^{111}In -DOTA-exendin-4 successfully detected two occult insulinomas not identified by conventional localizing study (42).

Selective arterial calcium stimulation (SACS) with hepatic venous sampling for insulin quantification, with an endpoint of a greater than twofold increase in hepatic venous insulin levels over baseline, has shown a high sensitivity (93%) for localization of insulinoma (28). The combination of SACS with EUS achieved tumor localization in all patients diagnosed in the period 1998–2007 at the Mayo Clinic, avoiding blind pancreatic exploration (28). Occult insulinomas are usually located within the pancreatic head (43, 44). Given the associated morbidity and lack of surgical success, blind distal pancreatectomy and progressive pancreatectomy are not recommended in cases of occult insulinoma at the present time (26, 44). Palpation and intraoperative ultrasonography (IOUS) permit detection of virtually all insulinomas, including reoperated cases (26, 44, 45). Lastly, the use of gamma-probe intraoperatively after ^{111}In -DOTA-exendin-4 administration permitted the detection and successful surgical removal of all insulinomas in a series of six patients, one of them with ectopic insulinoma (42).

Extrapancreatic (ectopic) insulinoma ▶ Ectopic insulinoma is an extremely rare (~2%) entity whose diagnosis should be suspected when a biochemically confirmed insulinoma is not localized (26). These tumors are usually located in the duodenal wall, although other locations such as duodenohepatic ligament and surrounding tissues of the pancreas have been reported (46, 47). Ectopic insulinomas usually develop on the ectopic (heterotopic, accessory, or aberrant) pancreas, an entity reported in 0.5–15% of autopsies and in 1 out of 500 abdominal surgeries, mainly found in the stomach, duodenum, and jejunum (46, 47, 48).

Insulinoma associated with multiple endocrine neoplasia type 1 ▶ Insulinoma is the second most common (10–30%) functioning pancreatic tumor associated with multiple endocrine neoplasia type 1 (MEN1), after

gastrinoma. On the contrary, only 4–6% of patients with insulinoma will develop *MEN1* (1, 28, 49). Unlike sporadic insulinomas that usually develop after the age of 40 years, MEN-associated insulinomas occur usually before 40 years of age and even before 20 years (24, 50). This explains why in 10% of *MEN1* patients insulinoma will be the first tumor to appear. On many occasions, tumors are multiple at the time of diagnosis and up to 10% can be associated with other pNETs (49). Metastases are present in up to 50% of patients with *MEN1*-associated insulinomas, compared with <10% of non-*MEN1* insulinomas (51). In the absence of distant metastases, surgery is advocated for *MEN1* insulinomas. Surgical therapy ranges from enucleation in isolated tumors to distal subtotal (80–85%) pancreatectomy combined with enucleation of tumors in the pancreatic head in those cases with multiple tumors (49, 51). Surgery is usually performed in *MEN1*-associated insulinoma even if the tumor cannot be identified by imaging due to the intense symptoms caused by hyperinsulinemia. Lastly, because insulinomas in these patients are usually multicentric, complete surgical resection is more difficult and local tumor resection often results in disease recurrence (52, 53).

Recurrent insulinoma ► Insulinoma-induced hypoglycemia can recur after successful surgical removal (54). It can develop from 4 to 20 years after initial surgery. Recurrence rate for insulinoma after initial pancreatic exploration was 5 and 7% at 10 and 20 years, respectively, in patients with sporadic insulinoma and 21% at 10–20 years in patients with *MEN1*, in a 60-year observation period study (from 1927 through 1986) performed in 224 Mayo Clinic patients (24). Recurrence of hyperinsulinemic hypoglycemia after a brief interval (<4 years) during which hypoglycemia (both symptomatic and biochemical) is absent suggests regrowth of remnant insulinoma (54).

Malignant insulinoma ► Approximately 5–10% of insulinomas are malignant with distant metastasis at diagnosis (Fig. 2), mainly to the liver and regional lymph nodes, with a reported 10-year survival rate of <20% (55). On many occasions, they are indolent tumors associated with prolonged survival. The patient can undergo pancreas and liver resection (if possible) during the same operation. Lymph node dissection should also be performed if there was evidence of nodal disease. Resection of liver metastases must be considered especially when metastatic disease is confined to the liver and surgery can remove >90% of tumor (27, 56). This surgery may provide

effective palliation and probably prolonged survival. Other approaches for the treatment of liver disease include hepatic artery embolization, radiofrequency ablation, and cryoablation (27). As opposed to benign insulinomas, malignant insulinomas often express somatostatin receptor subtype 2, showing positive somatostatin receptor scintigraphy in 73% of cases (57), which can be targeted therapeutically with long-acting somatostatin analogs and peptide radionuclide receptor therapy (58, 59).

Malignant insulinomas generally respond poorly to traditional chemotherapeutic agent regimens (fluorouracil, doxorubicin, and streptozocin) (60). Rapamycin (sirolimus) and everolimus, a rapamycin analog, are mammalian targets of rapamycin receptor antagonists that may provide a useful tool for stabilization of tumor growth and controlling hypoglycemia in malignant insulinomas by reducing the malignant β -cell growth and proliferation as well as inhibiting insulin production (60, 61, 62). In fact, the addition of everolimus resulted in abolition of hypoglycemia and stabilization of disease on imaging over 45 months in a patient with untreatable metastatic insulinoma and intractable hypoglycemia (62). In selected patients with unresectable liver metastases of malignant insulinoma, liver transplantation (LT) is a therapeutic option (63). Although this technique has achieved prolonged survival, up to 5 years, in some reported patients (64), the limited clinical experience due to the small sample size (4% of all cases of LT for metastatic NETs) (63) has led to this therapeutic procedure being currently considered as an investigational approach for patients with liver metastatic insulinoma.

Ectopic tumor insulin secretion: non-islet-cell tumors

A small number of non-islet-cell tumors have been associated with ectopic insulin secretion so far (Table 1) (18, 19, 20, 21, 22, 23). Among them are bronchial carcinoid tumor (18), squamous-cell carcinoma of the cervix (19), neurofibrosarcoma (65), schwannoma (20), paraganglioma (21, 23), small-cell carcinoma of the cervix (22), and gastrointestinal stromal tumor (66). Although in some of these cases there were alternative mechanisms for hypoglycemia and the possibility of pancreatic insulinoma was not definitely excluded, other more recent clinical reports (22, 23) have clearly shown that non-islet-cell tumors were the origin of the hyperinsulinemia on the basis of the detection of proinsulin mRNA and insulin protein within the tumor cells.

Mechanisms other than excess insulin

Tumor IGF2 precursors secretion (big IGF2) 'IGF2-oma'

NICTH due to IGF2 was initially reported by Daughaday *et al.* (1988) (67) in a 67-year-old woman who presented with recurrent severe hypoglycemia and a large thoracic leiomyosarcoma which resolved after tumor resection. The tumor showed high concentrations of *IGF2* mRNA and IGF2 immunoreactive in form of a large precursor molecule, and a similar fraction of high-molecular-weight IGF2 in the patient's serum. Since the first report there have been many clinical cases of NICTH secondary to IGF2 tumor hypersecretion by other types of tumors (3, 4, 5, 6, 7, 8, 9, 10, 11, 68) (Table 1). This pathogenic mechanism is the main cause of NICTH (2, 69) and the term 'IGF2-oma' has been proposed to describe these types of tumors (70).

The main mechanism in IGF2-induced NICTH is the overexpression of the *IGF2* gene (structurally homologous to the insulin gene) by the tumor which is associated by the tumor secretion of incompletely processed precursors of IGF2 (pro-IGF2 or big IGF2) with a persistent insulin-like activity (2, 69, 71, 72). Pro-IGF2 is expressed in a broad spectrum of malignant and benign tumors and binds poorly to its binding proteins, thus increasing the likelihood that the molecule freely penetrates tissue spaces. Big IGF2 suppresses both GH and insulin at pituitary and pancreas levels respectively. Owing to the suppression of GH secretion, synthesis and secretion of IGF1 and IGF-binding protein 3 (IGFBP3) are also decreased. Although the serum level of total IGF2 may be normal, both the ratios pro-IGF2:IGF2 and IGF2:IGF1 may be elevated (2, 69, 73). In one study, the IGF2:IGF1 ratio ranged from 16.4 to 64.2 with a mean of 35.0 ± 2.2 in

a group of patients with NICTH with big IGF2 (69). Lastly, basal-immunoreactive insulin levels are low in these patients (69, 74) (Table 2). The elevated bioavailability of both big and free IGF2 increases peripheral glucose consumption and decreases glucose production in the liver giving rise to the development of hypoglycemia (1, 2, 69).

In a retrospective study performed in 78 patients (44 males, 56%; age at diagnosis 62 ± 1.8 years, range; 9–86 years) with NICTH and high serum levels of big IGF2, Fukuda *et al.* (2006) (69) found that hypoglycemic attack (confusion, incoordination, difficulty in waking in the morning, and sweating and coma) was the onset of disease in 48%, but the tumor was revealed before the occurrence of hypoglycemia in 52%. Hepatocellular carcinoma and gastric carcinoma were the most common causes of NICTH and the diameters of the tumors were more than 10 cm in 70% of the patients. All these data suggest that hypoinsulinemic hypoglycemia associated with the presence of a large tumor supports the diagnosis of IGF2 producing NICTH (69).

Treatment should be aimed at immediate correction of hypoglycemia, followed by treatment directed at the underlying tumor and, finally, prevention of recurrent hypoglycemia if the tumor cannot be cured. In these cases, long-term management with glucocorticoid therapy has been demonstrated to consistently reverse the biochemical abnormalities caused by tumor-derived big IGF2 and it has been suggested that this therapy alone or in combination with human growth hormone, with or without the addition of long-acting glucagon, is the most effective therapy in alleviating intractable hypoglycemia (75).

Table 2 Pathogenic mechanisms and types of tumors associated with tumor-induced hypoglycemia.

	Insulin	GH	IGF1	IGF2	Big IGF2	IGFBP3	Others	Associated clinical disorders
Insulinoma	↑	–	–	–	–	–	High levels of C-peptide and proinsulin Negative sulphonylurea and circulating insulin autoantibodies	MEN1 (~ 10%)
IGF2-oma	↓	↓	↓	↔/↑	↑↑	↓	Increased ratios: pro-IGF2:IGF2 and IGF2:IGF1	
Somatostatinoma	↓	↓	↔↓	?	?	?	High somatostatin Low counter-regulatory hormones levels	Type 2 diabetes Cholelithiasis Diarrhea
IGF1-oma	↓	↔	↑↑	↔	↔	↔		Acromegaly (?)
GLP1-oma	–	–	–	–	–	–	High levels of glucagon, somatostatin and GLP1	Type 2 diabetes
Tumor autoimmune hypoglycemia	↑↑	–	–	–	–	–	Autoantibodies to insulin or insulin receptor	Hematological malignancies

Tumor somatostatin secretion 'Somatostatinoma'

Somatostatin-producing tumors or somatostatinomas are rare NETs (~1% of gastroenteropancreatic-NETs) derived from D cells with an annual incidence of 1 in 40 million (76). Since its first description by Larsson *et al.* (1977) (77), about 200 cases have been reported. Somatostatinomas usually arise in the pancreas and duodenum (~90%) with approximately equal frequency (78, 79). Extrapaneatic somatostatinomas (carcinoid somatostatinomas) can arise in other locations such as jejunum (80) and ovary (81). The most common symptoms are abdominal pain and weight loss and, in some instances (~10%) they produce somatostatinoma syndrome (diabetes mellitus, cholelithiasis, and diarrhea with steatorrhea) due to excessive secretion of somatostatin, a hormone that inhibits gastrointestinal motility and secretion as well as the release of many hormones including insulin and glucagon. Somatostatinoma-induced hypoglycemia is uncommon with isolated cases reported to date (81, 82, 83, 84). In three out of four reported cases, the tumor was located in the pancreas (82, 83, 84) and only one in the ovary (81). The mechanism of somatostatinoma-induced hypoglycemia is not clear. It seems to be related to the suppression of glucagon, GH, and other counter-regulatory hormones by somatostatin. As somatostatin-producing endocrine tumors are frequently malignant (~70), surgical resection is the first-line therapy for localized tumors (85). Hypoglycemia is rarely sensitive to the hyperglycemic effects of diazoxide (82). Blood glucose level is usually stabilized after surgery (81, 84) or chemotherapy (82).

Tumor IGF1 secretion 'IGF1-oma'

NICTH due to overproduction and secretion of IGF1 (IGF1-oma) is an exceptional event. In fact, to our knowledge, only one patient has been reported so far (12). She was a 64-year-old woman admitted due to severe recurrent non-hyperinsulinemic hypoglycemia. No signs of acromegaly were present. The patient was diagnosed with pulmonary large cell carcinoma with axillary metastasis. Serum total and free IGF1 concentrations were elevated, whereas GH, IGFBP3, acid-labile subunit, and big IGF2 were normal, and serum insulin and C-peptide were suppressed. Immunohistochemistry demonstrated IGF1 peptide in some tumor cells and *IGF1* mRNA was detected by *in situ* hybridization in virtually all tumor cells. Hypoglycemic episodes did not recur after chemotherapy. The mechanism of hypoglycemia proposed

by the authors would be related with an increase in the amount of free IGF1 which would reach insulin target tissues exerting insulin-like effects. The absence of acromegalic features might be explained by the absence of a sustained combined elevation of GH and IGF1 and the relatively short duration of paraneoplastic hormonal changes (12).

Tumor GLP1 secretion 'GLP1-oma'

GLP1 is a gut peptide that stimulates both insulin release from pancreatic β -cells and β -cell hyperplasia. Paraneoplastic GLP1 hypersecretion causing reactive hypoglycemia was initially reported in 2003 in a patient with an ovarian NET (15). She was a 45-year-old woman with type 2 diabetes who developed episodes of symptomatic postprandial hypoglycemia which were cured with tumor surgery. Nine years later, in 2012, a second clinical case was reported (16). He was a 56-year-old male with a previous diagnosis of diabetes who presented with fasting hypoglycemia. Clinical study demonstrated a glucagon-secreting pNET, which was the likely cause of diabetes, whereas hypoglycemia was caused by insulin secretion from hyperplastic β -cells stimulated by metastases-derived GLP1. However, severe hypoglycemia is not always associated with GLP1 tumor secretion. In fact, two other patients with GLP1- and GLP2-producing NETs and with the absence of symptomatic hypoglycemia have been previously reported (86, 87).

Autoantibodies to insulin or its receptor 'Tumor autoimmune hypoglycemia'

The syndrome of autoimmune hypoglycemia is an uncommon cause of hypoglycemia characterized by elevated levels of insulin in the presence of either anti-insulin antibodies (insulin autoimmune syndrome, Hirata disease) or anti-insulin receptor antibodies (type B insulin resistance) (88, 89, 90). Autoimmune hypoglycemia has also been related to tumor hypoglycemia (13, 90, 91). In this case, anti-insulin antibodies or anti-insulin receptor antibodies are produced by the tumor (13). Both conditions are usually associated with inappropriately elevated insulin and they can lead to fasting hypoglycemia, postprandial hypoglycemia, or both (90). Several tumors have been associated with autoimmune hypoglycemia, among them are multiple myeloma (13, 92), chronic myelomonocytic leukemia (90), and Hodgkin's disease (91).

Other tumor-related factors

Tumor hypoglycemia may be due exclusively to increased glucose consumption by the tumor mass and/or its metastases, as well as in those with massive liver tumor infiltration (93, 94, 95, 96, 97). Among these tumors are hepatocellular carcinoma (95, 96), meningioma (93, 94), non-Hodgkin's lymphoma (98, 99), and pheochromocytoma (97). Excessive tumor glucose consumption can become manifested through functional tests such as ¹⁸F-2-fluoro-2-deoxy-D-glucose positron emission tomography/CT (¹⁸F-FDG–PET/CT), showing remarkable glucose uptake in the tumor with reduced physiologic uptake in other organs (97). On other occasions, the tumor can infiltrate and destroy different organs, such as the pituitary or adrenal glands, resulting in hypopituitarism or primary adrenal insufficiency, respectively, giving rise to the development of secondary hypoglycemia (100).

Conclusion

Tumors are a rare cause of hypoglycemia. TIH is usually due to the tumor hypersecretion of insulin by pancreatic β cell-derived tumors (insulinomas). However, there are other tumors that have the capability of producing hypoglycemia by mechanisms other than the endogenous hyperinsulinism. This diagnostic possibility should be kept in mind because hypoglycemia in this case can manifest as paraneoplastic symptoms of a tumor with a potentially serious prognosis.

Declaration of interest

The authors declare that there is no conflict of interest that could be perceived as prejudicing the impartiality of the review.

Funding

This review did not receive any specific grant from any funding agency in the public, commercial or not-for-profit sector.

References

- Cryer PE, Axelrod L, Grossman AB, Heller SR, Montori VM, Seaquist ER, Service FJ & Endocrine Society. Evaluation and management of adult hypoglycemic disorders: an Endocrine Society Clinical Practice Guideline. *Journal of Clinical Endocrinology and Metabolism* 2009 **94** 709–728. (doi:10.1210/jc.2008-1410)
- de Groot JW, Rijkhof B, van Doorn J, Bilo HJ, Alleman MA, Honkoop AH & van der Graaf WT. Non-islet cell tumour-induced hypoglycaemia: a review of the literature including two new cases. *Endocrine-Related Cancer* 2007 **14** 979–993. (doi:10.1677/ERC-07-0161)
- Gorden P, Hendricks CM, Kahn CR, Megyesi K & Roth J. Hypoglycemia associated with non-islet-cell tumor and insulin-like growth factors. *New England Journal of Medicine* 1981 **305** 1452–1455. (doi:10.1056/NEJM198112103052405)
- Daughaday WH & Kapadia M. Significance of abnormal serum binding of insulin-like growth factor II in the development of hypoglycemia in patients with non-islet-cell tumors. *PNAS* 1989 **86** 6778–6782. (doi:10.1073/pnas.86.17.6778)
- Shapiro ET, Bell GI, Polonsky KS, Rubenstein AH, Kew MC & Tager HS. Tumor hypoglycemia: relationship to high molecular weight insulin-like growth factor-II. *Journal of Clinical Investigation* 1990 **85** 1672–1679. (doi:10.1172/JCI114619)
- O'Loughlin A, Waldron-Lynch F, Cronin KC, Dinneen S, Lee J, Griffin D, Casey M, Nusrat N, Jaffrey S, O'Brien T *et al.* When a nephrectomy cures hypoglycaemia. *BMJ Case Reports* 2009 **2009** bcr0220091617. (doi:10.1136/bcr.02.2009.1617)
- Ishikura K, Takamura T, Takeshita Y, Nakagawa A, Imaizumi N, Misu H, Taji K, Kasahara K, Oshino Y, Suzuki S *et al.* Cushing's syndrome and big IGF-II associated hypoglycaemia in a patient with adrenocortical carcinoma. *BMJ Case Reports* 2010 **2010** bcr07.2009.2100. (doi:10.1136/bcr.07.2009.2100)
- Barra WF, Castro G, Hoff AO, Siqueira SA & Hoff PM. Symptomatic hypoglycemia related to inappropriately high igf-ii serum levels in a patient with desmoplastic small round cell tumor. *Case Reports in Medicine* 2010 **2010** 684045. (doi:10.1155/2010/684045)
- Macfarlane DP & Leese GP. Hypoglycaemia, phaeochromocytoma and features of acromegaly: a unifying diagnosis? *QJM: Monthly Journal of the Association of Physicians* 2011 **104** 983–986. (doi:10.1093/qjmed/hcq219)
- Ndzengue A, Deribe Z, Rafal RB, Mora M, Desgrottes S, Schmidt F, Becher R, Wright AM, Guillaume J & Jaffe EA. Non-islet cell tumor hypoglycemia associated with uterine leiomyomata. *Endocrine Practice* 2011 **17** e109–e112. (doi:10.4158/EP10381.CR)
- Chan JK, Cheuk W, Ho LC & Wen JM. Recurrent meningeal hemangiopericytoma with multiple metastasis and hypoglycemia: a case report. *Case Reports in Medicine* 2012 **2012** 628756.
- Nauck MA, Reinecke M, Perren A, Frystyk J, Berishvili G, Zwimpfer C, Figge AM, Flyvbjerg A, Lankisch PG, Blum WF *et al.* Hypoglycemia due to paraneoplastic secretion of insulin-like growth factor-I in a patient with metastasizing large-cell carcinoma of the lung. *Journal of Clinical Endocrinology and Metabolism* 2007 **92** 1600–1605. (doi:10.1210/jc.2006-2573)
- Redmon B, Pyzdrowski KL, Elson MK, Kay NE, Dalmaso AP & Nuttall FQ. Hypoglycemia due to an insulin-binding monoclonal antibody in multiple myeloma. *New England Journal of Medicine* 1992 **326** 994–998. (doi:10.1056/NEJM199204093261505)
- Braund WJ, Naylor BA, Williamson DH, Buley ID, Clark A, Chapel HM & Turner RC. Autoimmunity to insulin receptor and hypoglycaemia in patient with Hodgkin's disease. *Lancet* 1987 **1** 237–240. (doi:10.1016/S0140-6736(87)90063-8)
- Todd JF, Stanley SA, Roufosse CA, Bishop AE, Khoo B, Bloom SR & Meeran K. A tumour that secretes glucagon-like peptide-1 and somatostatin in a patient with reactive hypoglycaemia and diabetes. *Lancet* 2003 **361** 228–230. (doi:10.1016/S0140-6736(03)12256-8)
- Roberts RE, Zhao M, Whitelaw BC, Ramage J, Diaz-Cano S, le Roux CW, Quaglia A, Huang GC & Aylwin SJ. GLP-1 and glucagon secretion from a pancreatic neuroendocrine tumor causing diabetes and hyperinsulinemic hypoglycemia. *Journal of Clinical Endocrinology and Metabolism* 2012 **97** 3039–3045. (doi:10.1210/jc.2011-2005)
- Wu L, Wu J & Zhang H. Hypoglycemia-induced convulsive status epilepticus as the initial presentation of primary hepatic carcinoma. *Neurological Sciences* 2012 **33** 1469–1471. (doi:10.1007/s10072-012-0985-1)
- Shames JM, Dhurandhar NR & Blackard WG. Insulin-secreting bronchial carcinoid tumor with widespread metastases. *American Journal of Medicine* 1968 **44** 632–637. (doi:10.1016/0002-9343(68)90065-X)

- 19 Kiang DT, Bauer GE & Kennedy BJ. Immunoassayable insulin in carcinoma of the cervix associated with hypoglycemia. *Cancer* 1973 **31** 801–805. (doi:10.1002/1097-0142(197304)31:4<801::AID-CNCR2820310407>3.0.CO;2;J)
- 20 Shetty MR, Boghossian HM, Duffell D, Freel R & Gonzales JC. Tumor-induced hypoglycemia: a result of ectopic insulin production. *Cancer* 1982 **49** 1920–1923. (doi:10.1002/1097-0142(19820501)49:9<1920::AID-CNCR2820490927>3.0.CO;2-M)
- 21 Fujino K, Yamamoto S, Matsumoto M, Sunada M & Ota T. Paraganglioma associated with hypoglycemia. *Internal Medicine* 1992 **31** 1239–1241. (doi:10.2169/internalmedicine.31.1239)
- 22 Seckl MJ, Mulholland PJ, Bishop AE, Teale JD, Hales CN, Glaser M, Watkins S & Seckl JR. Hypoglycemia due to an insulin-secreting small-cell carcinoma of the cervix. *New England Journal of Medicine* 1999 **341** 733–736. (doi:10.1056/NEJM199909023411004)
- 23 Uysal M, Temiz S, Gul N, Yarman S, Tanakol R & Kapran Y. Hypoglycemia due to ectopic release of insulin from a paraganglioma. *Hormone Research* 2007 **67** 292–295. (doi:10.1159/000099291)
- 24 Service FJ, McMahon MM, O'Brien PC & Ballard DJ. Functioning insulinoma – incidence, recurrence, and long-term survival of patients: a 60-year study. *Mayo Clinic Proceedings* 1991 **66** 711–719. (doi:10.1016/S0025-6196(12)62083-7)
- 25 Grant CS. Insulinoma. *Best Practice & Research. Clinical Gastroenterology* 2005 **19** 783–798. (doi:10.1016/j.bpg.2005.05.008)
- 26 Abboud B & Boujaoude J. Occult sporadic insulinoma: localization and surgical strategy. *World Journal of Gastroenterology* 2008 **14** 657–665. (doi:10.3748/wjg.14.657)
- 27 Oberg K, Knigge U, Kwekkeboom D, Perren A & ESMO Guidelines Working Group. Neuroendocrine gastro-entero-pancreatic tumors: ESMO Clinical Practice Guidelines for diagnosis, treatment and follow-up. *Annals of Oncology* 2012 **7** vii124–vii130.
- 28 Placzkowski KA, Vella A, Thompson GB, Grant CS, Reading CC, Charboneau JW, Andrews JC, Lloyd RV & Service FJ. Secular trends in the presentation and management of functioning insulinoma at the Mayo Clinic, 1987–2007. *Journal of Clinical Endocrinology and Metabolism* 2009 **94** 1069–1073. (doi:10.1210/jc.2008-2031)
- 29 Tucker ON, Crotty PL & Conlon KC. The management of insulinoma. *British Journal of Surgery* 2006 **93** 264–275. (doi:10.1002/bjs.5280)
- 30 Cryer PE. Symptoms of hypoglycemia, thresholds for their occurrence, and hypoglycemia unawareness. *Endocrinology and Metabolism Clinics of North America* 1999 **28** 495–500 (v–vi). (doi:10.1016/S0889-8529(05)70084-0)
- 31 Kokkoris P & Pi-Sunyer FX. Obesity and endocrine disease. *Endocrinology and Metabolism Clinics of North America* 2003 **32** 895–914. (doi:10.1016/S0889-8529(03)00078-1)
- 32 Bonfig W, Kann P, Rothmund M & Schwarz HP. Recurrent hypoglycemic seizures and obesity: delayed diagnosis of an insulinoma in a 15 year-old boy – final diagnostic localization with endosonography. *Journal of Pediatric Endocrinology & Metabolism* 2007 **20** 1035–1038. (doi:10.1515/JPEM.2007.20.9.1035)
- 33 Noone TC, Hosey J, Firat Z & Semelka RC. Imaging and localization of islet-cell tumours of the pancreas on CT and MRI. *Best Practice & Research. Clinical Endocrinology & Metabolism* 2005 **19** 195–211. (doi:10.1016/j.beem.2004.11.013)
- 34 Virgolini I, Traub-Weidinger T & Decristoforo C. Nuclear medicine in the detection and management of pancreatic islet-cell tumours. *Best Practice & Research. Clinical Endocrinology & Metabolism* 2005 **19** 213–227. (doi:10.1016/j.beem.2004.09.001)
- 35 Ayav A, Bresler L, Brunaud L & Boissel P. SFCL (Societe Francaise de Chirurgie Laparoscopique) & AFCE (Association Francophone de Chirurgie Endocrinienne). Laparoscopic approach for solitary insulinoma: a multicentre study. *Langenbeck's Archives of Surgery* 2005 **390** 134–140. (doi:10.1007/s00423-004-0526-3)
- 36 Luo Y, Liu R, Hu MG, Mu YM, An LC & Huang ZQ. Laparoscopic surgery for pancreatic insulinomas: a single-institution experience of 29 cases. *Journal of Gastrointestinal Surgery* 2009 **13** 945–950. (doi:10.1007/s11605-009-0830-x)
- 37 Toniato A, Meduri F, Foletto M, Avogaro A & Pelizzo M. Laparoscopic treatment of benign insulinomas localized in the body and tail of the pancreas: a single-center experience. *World Journal of Surgery* 2006 **30** 1916–1919 (discussion 1920–1921). (doi:10.1007/s00268-005-0645-1)
- 38 Levy MJ, Thompson GB, Topazian MD, Callstrom MR, Grant CS & Vella A. US-guided ethanol ablation of insulinomas: a new treatment option. *Gastrointestinal Endoscopy* 2012 **75** 200–206. (doi:10.1016/j.gie.2011.09.019)
- 39 Bao ZK, Huang XY, Zhao JG, Zheng Q, Wang XF & Wang HC. A case of occult insulinoma localized by pancreatic dynamic enhanced spiral CT. *World Journal of Gastroenterology* 2010 **16** 1418–1421. (doi:10.3748/wjg.v16.i11.1418)
- 40 Zimmer T, Stolzel U, Bader M, Koppenhagen K, Hamm B, Buhr H, Riecken EO & Wiedenmann B. Endoscopic ultrasonography and somatostatin receptor scintigraphy in the preoperative localisation of insulinomas and gastrinomas. *Gut* 1996 **39** 562–568. (doi:10.1136/gut.39.4.562)
- 41 Wild D, Macke H, Christ E, Gloor B & Reubi JC. Glucagon-like peptide 1-receptor scans to localize occult insulinomas. *New England Journal of Medicine* 2008 **359** 766–768. (doi:10.1056/NEJMc0802045)
- 42 Christ E, Wild D, Forrer F, Brandle M, Sahli R, Clerici T, Gloor B, Martius F, Maecke H & Reubi JC. Glucagon-like peptide-1 receptor imaging for localization of insulinomas. *Journal of Clinical Endocrinology and Metabolism* 2009 **94** 4398–4405. (doi:10.1210/jc.2009-1082)
- 43 Norton JA, Shawker TH, Doppman JL, Miller DL, Fraker DL, Cromack DT, Gorden P & Jensen RT. Localization and surgical treatment of occult insulinomas. *Annals of Surgery* 1990 **212** 615–620. (doi:10.1097/0000658-199011000-00009)
- 44 Hirshberg B, Libutti SK, Alexander HR, Bartlett DL, Cochran C, Livi A, Chang R, Shawker T, Skarulis MC & Gorden P. Blind distal pancreatectomy for occult insulinoma, an inadvisable procedure. *Journal of the American College of Surgeons* 2002 **194** 761–764. (doi:10.1016/S1072-7515(02)01177-8)
- 45 Hiramoto JS, Feldstein VA, LaBerge JM & Norton JA. Intraoperative ultrasound and preoperative localization detects all occult insulinomas; discussion 1025–6. *Archives of Surgery* 2001 **136** 1020–1025. (doi:10.1001/archsurg.136.9.1020)
- 46 Hennings J, Garske U, Botling J & Hellman P. Malignant insulinoma in ectopic pancreatic tissue. *Digestive Surgery* 2005 **22** 377–379. (doi:10.1159/000090998)
- 47 Xian-Ling W, Yi-Ming M, Jing-Tao D, Wen-Wen Z, Zhao-Hui L, Rong L & Ju-Ming L. Successful laparoscope resection of ectopic insulinoma in duodenohepatic ligament. *American Journal of the Medical Sciences* 2011 **341** 420–422. (doi:10.1097/MAJ.0b013e31820b8a67)
- 48 Ouro S, Tare F & Moniz L. Pancreatic ectopia. *Acta Médica Portuguesa* 2011 **24** 361–366.
- 49 Thakker RV, Newey PJ, Walls GV, Bilezikian J, Dralle H, Ebeling PR, Melmed S, Sakurai A, Tonelli F & Brandi ML. Clinical practice guidelines for multiple endocrine neoplasia type 1 (MEN1). *Journal of Clinical Endocrinology and Metabolism* 2012 **97** 2990–3011. (doi:10.1210/jc.2012-1230)
- 50 Machens A, Schaaf L, Karges W, Frank-Raue K, Bartsch DK, Rothmund M, Schneyer U, Goretzki P, Raue F & Dralle H. Age-related penetrance of endocrine tumours in multiple endocrine neoplasia type 1 (MEN1): a multicentre study of 258 gene carriers. *Clinical Endocrinology* 2007 **67** 613–622.
- 51 Akerstrom G & Hellman P. Surgery on neuroendocrine tumours. *Best Practice & Research. Clinical Endocrinology & Metabolism* 2007 **21** 87–109. (doi:10.1016/j.beem.2006.12.004)
- 52 Finlayson E & Clark OH. Surgical treatment of insulinomas. *Surgical Clinics of North America* 2004 **84** 775–785. (doi:10.1016/j.suc.2004.02.004)

- 53 Niina Y, Fujimori N, Nakamura T, Igarashi H, Oono T, Nakamura K, Kato M, Jensen RT, Ito T & Takayanagi R. The current strategy for managing pancreatic neuroendocrine tumors in multiple endocrine neoplasia type 1. *Gut and Liver* 2012 **6** 287–294. (doi:10.5009/gnl.2012.6.3.287)
- 54 Service FJ. Recurrent hyperinsulinemic hypoglycemia caused by an insulin-secreting insulinoma. *Nature Clinical Practice. Endocrinology & Metabolism* 2006 **2** 467–470 (quiz following 470). (doi:10.1038/ncpendmet0263)
- 55 Starke A, Saddig C, Mansfeld L, Koester R, Tschahargane C, Czygan P & Goretzki P. Malignant metastatic insulinoma-postoperative treatment and follow-up. *World Journal of Surgery* 2005 **29** 789–793. (doi:10.1007/s00268-005-7743-y)
- 56 Alexakis N & Neoptolemos JP. Pancreatic neuroendocrine tumours. *Best Practice & Research. Clinical Gastroenterology* 2008 **22** 183–205. (doi:10.1016/j.bpg.2007.10.008)
- 57 Wild D, Christ E, Caplin ME, Kurzawinski TR, Forrer F, Brandle M, Seufert J, Weber WA, Bomanji J, Perren A *et al*. Glucagon-like peptide-1 versus somatostatin receptor targeting reveals 2 distinct forms of malignant insulinomas. *Journal of Nuclear Medicine* 2011 **52** 1073–1078. (doi:10.2967/jnumed.110.085142)
- 58 Chandra P, Yarandi SS, Khazai N, Jacobs S & Umpierrez GE. Management of intractable hypoglycemia with Yttrium-90 radioembolization in a patient with malignant insulinoma. *American Journal of the Medical Sciences* 2010 **340** 414–417. (doi:10.1097/MAJ.0b013e3181ee7be2)
- 59 Fischbach J, Gut P, Matysiak-Grzes M, Klimowicz A, Gryczynska M, Wasko R & Ruchala M. Combined octreotide and peptide receptor radionuclide therapy (90Y-DOTA-TATE) in case of malignant insulinoma. *Neuro Endocrinology Letters* 2012 **33** 273–278.
- 60 Kulke MH, Bergsland EK & Yao JC. Glycemic control in patients with insulinoma treated with everolimus. *New England Journal of Medicine* 2009 **360** 195–197. (doi:10.1056/NEJMc0806740)
- 61 Bourcier ME, Sherrod A, DiGuardo M & Vinik AI. Successful control of intractable hypoglycemia using rapamycin in an 86-year-old man with a pancreatic insulin-secreting islet cell tumor and metastases. *Journal of Clinical Endocrinology and Metabolism* 2009 **94** 3157–3162. (doi:10.1210/jc.2009-0788)
- 62 Thomas N, Brooke A & Besser G. Long-term maintenance of normoglycaemia using everolimus in a patient with disseminated insulinoma and severe hypoglycaemia. *Clinical Endocrinology* 2013 **78** 799–800. (doi:10.1111/cen.12059)
- 63 Gedaly R, Daily MF, Davenport D, McHugh PP, Koch A, Angulo P & Hundley JC. Liver transplantation for the treatment of liver metastases from neuroendocrine tumors: an analysis of the UNOS database. *Archives of Surgery* 2011 **146** 953–958. (doi:10.1001/archsurg.2011.186)
- 64 Chen XB, Yang J, Xu MQ & Yan LN. Liver transplantation for hepatic metastatic pancreatic insulinoma with a survival over five years. *Chinese Medical Journal* 2012 **125** 2768–2771.
- 65 Lyall SS, Marieb NJ, Wise JK, Cornog JL, Neville EC & Felig P. Hyperinsulinemic hypoglycemia associated with a neurofibrosarcoma. *Archives of Internal Medicine* 1975 **135** 865–867. (doi:10.1001/archinte.1975.00330060109016)
- 66 Hall KF, Lin CL, Wang TH, Chang RH & Chen HM. A case of gastrointestinal stromal tumor with hyperinsulinemic hypoglycemia. *Chang Gung Medical Journal* 2008 **31** 107–111.
- 67 Daughaday WH, Emanuele MA, Brooks MH, Barbato AL, Kapadia M & Rotwein P. Synthesis and secretion of insulin-like growth factor II by a leiomyosarcoma with associated hypoglycemia. *New England Journal of Medicine* 1988 **319** 1434–1440. (doi:10.1056/NEJM198812013192202)
- 68 Chan G, Horton PJ, Thyssen S, Lamarche M, Nahal A, Hill DJ, Marliss EB & Metrakos P. Malignant transformation of a solitary fibrous tumor of the liver and intractable hypoglycemia. *Journal of Hepato-Biliary-Pancreatic Surgery* 2007 **14** 595–599. (doi:10.1007/s00534-007-1210-0)
- 69 Fukuda I, Hizuka N, Ishikawa Y, Yasumoto K, Murakami Y, Sata A, Morita J, Kurimoto M, Okubo Y & Takano K. Clinical features of insulin-like growth factor-II producing non-islet-cell tumor hypoglycemia. *Growth Hormone & IGF Research* 2006 **16** 211–216. (doi:10.1016/j.ghir.2006.05.003)
- 70 Dynkevich Y, Rother KI, Whitford I, Qureshi S, Galiveeti S, Szulc AL, Danoff A, Breen TL, Kaviani N, Shanik MH *et al*. Tumors, IGF-2 and hypoglycemia: insights from the clinic, the laboratory and the historical archive. *Endocrine Reviews* 2013 **34** 798–826. (doi:10.1210/er.2012-1033)
- 71 Marks V & Teale JD. Tumours producing hypoglycaemia. *Diabetes/Metabolism Reviews* 1991 **7** 79–91. (doi:10.1002/dmr.5610070202)
- 72 Service FJ. Hypoglycemic disorders. *New England Journal of Medicine* 1995 **332** 1144–1152. (doi:10.1056/NEJM199504273321707)
- 73 Pelosof LC & Gerber DE. Paraneoplastic syndromes: an approach to diagnosis and treatment. *Mayo Clinic Proceedings* 2010 **85** 838–854. (doi:10.4065/mcp.2010.0099)
- 74 Miraki-Moud F, Grossman AB, Besser M, Monson JP & Camacho-Hubner C. A rapid method for analyzing serum pro-insulin-like growth factor-II in patients with non-islet cell tumor hypoglycemia. *Journal of Clinical Endocrinology and Metabolism* 2005 **90** 3819–3823. (doi:10.1210/jc.2004-2090)
- 75 Teale JD & Marks V. Glucocorticoid therapy suppresses abnormal secretion of big IGF-II by non-islet cell tumours inducing hypoglycaemia (NICTH). *Clinical Endocrinology* 1998 **49** 491–498. (doi:10.1046/j.1365-2265.1998.00564.x)
- 76 Williamson JM, Thorn CC, Spalding D & Williamson RC. Pancreatic and peripancreatic somatostatinomas. *Annals of the Royal College of Surgeons of England* 2011 **93** 356–360. (doi:10.1308/003588411X582681)
- 77 Larsson LI, Hirsch MA, Holst JJ, Ingemansson S, Kuhl C, Jensen SL, Lundqvist G, Rehfeld JF & Schwartz TW. Pancreatic somatostatinoma. Clinical features and physiological implications. *Lancet* 1977 **1** 666–668. (doi:10.1016/S0140-6736(77)92113-4)
- 78 Moayedoddin B, Booya F, Wermers RA, Lloyd RV, Rubin J, Thompson GB & Fatourehchi V. Spectrum of malignant somatostatin-producing neuroendocrine tumors. *Endocrine Practice* 2006 **12** 394–400. (doi:10.4158/EP.12.4.394)
- 79 Soga J & Yakuwa Y. Somatostatinoma/inhibitory syndrome: a statistical evaluation of 173 reported cases as compared to other pancreatic endocrinomas. *Journal of Experimental & Clinical Cancer Research* 1999 **18** 13–22.
- 80 Nesi G, Marcucci T, Rubio CA, Brandi ML & Tonelli F. Somatostatinoma: clinico-pathological features of three cases and literature reviewed. *Journal of Gastroenterology and Hepatology* 2008 **23** 521–526. (doi:10.1111/j.1440-1746.2007.05053.x)
- 81 Sugiyama T, Nakanishi M, Hoshimoto K, Uebanso T, Inoue K, Endo H, Minoura S, Yasuda K & Noda M. Severely fluctuating blood glucose levels associated with a somatostatin-producing ovarian neuroendocrine tumor. *Journal of Clinical Endocrinology and Metabolism* 2012 **97** 3845–3850. (doi:10.1210/jc.2012-2091)
- 82 Wright J, Abolfathi A, Penman E & Marks V. Pancreatic somatostatinoma presenting with hypoglycaemia. *Clinical Endocrinology* 1980 **12** 603–608. (doi:10.1111/j.1365-2265.1980.tb01382.x)
- 83 Cao XP, Liu YY, Xiao HP, Li YB, Wang LT & Xiao P. Pancreatic somatostatinoma characterized by extreme hypoglycemia. *Chinese Medical Journal* 2009 **122** 1709–1712.
- 84 He X, Wang J, Wu X, Kang L & Lan P. Pancreatic somatostatinoma manifested as severe hypoglycemia. *Journal of Gastrointestinal and Liver Diseases* 2009 **18** 221–224.
- 85 Garbrecht N, Anlauf M, Schmitt A, Henopp T, Sipos B, Raffel A, Eisenberger CF, Knoefel WT, Pavel M, Fottner C *et al*. Somatostatin-producing neuroendocrine tumors of the duodenum and pancreas: incidence, types, biological behavior, association with inherited syndromes, and functional activity. *Endocrine-Related Cancer* 2008 **15** 229–241. (doi:10.1677/ERC-07-0157)

- 86 Byrne MM, McGregor GP, Barth P, Rothmund M, Goke B & Arnold R. Intestinal proliferation and delayed intestinal transit in a patient with a GLP-1-, GLP-2- and PYY-producing neuroendocrine carcinoma. *Digestion* 2001 **63** 61–68. (doi:10.1159/000051874)
- 87 Brubaker PL, Drucker DJ, Asa SL, Swallow C, Redston M & Greenberg GR. Prolonged gastrointestinal transit in a patient with a glucagon-like peptide (GLP)-1- and -2-producing neuroendocrine tumor. *Journal of Clinical Endocrinology and Metabolism* 2002 **87** 3078–3083. (doi:10.1210/jcem.87.7.8584)
- 88 Uchigata Y & Hirata Y. Insulin autoimmune syndrome (IAS, Hirata disease). *Annales de Medecine Interne* 1999 **150** 245–253.
- 89 Basu A, Service FJ, Yu L, Hesser D, Ferries LM & Eisenbarth G. Insulin autoimmunity and hypoglycemia in seven white patients. *Endocrine Practice* 2005 **11** 97–103. (doi:10.4158/EP.11.2.97)
- 90 Lupsa BC, Chong AY, Cochran EK, Soos MA, Semple RK & Gordon P. Autoimmune forms of hypoglycemia. *Medicine* 2009 **88** 141–153. (doi:10.1097/MD.0b013e3181a5b42e)
- 91 Kulkarni A, Zlabek J, Farnen J & Capla R. Recurrent hypoglycemia and hypothermia in a patient with Hodgkin's disease. *Haematologica* 2006 **91** ECR50.
- 92 Halsall DJ, Mangi M, Soos M, Fahie-Wilson MN, Wark G, Mainwaring-Burton R & O'Rahilly S. Hypoglycemia due to an insulin binding antibody in a patient with an IgA-kappa myeloma. *Journal of Clinical Endocrinology and Metabolism* 2007 **92** 2013–2016. (doi:10.1210/jc.2007-0075)
- 93 Phuphanich S, Jacobs L, Poulos JE & Vesely DL. Case report: Hypoglycemia secondary to a meningioma. *American Journal of the Medical Sciences* 1995 **309** 317–321. (doi:10.1097/00000441-199506000-00004)
- 94 Yoshida D, Sugisaki Y, Tamaki T, Saitoh N, Node Y, Shimura T & Teramoto A. Intracranial malignant meningioma with abdominal metastases associated with hypoglycemic shock: a case report. *Journal of Neuro-Oncology* 2000 **47** 51–58. (doi:10.1023/A:1006460827300)
- 95 Sorlini M, Benini F, Cravarezza P & Romanelli G. Hypoglycemia, an atypical early sign of hepatocellular carcinoma. *Journal of Gastrointestinal Cancer* 2010 **41** 209–211. (doi:10.1007/s12029-010-9137-0)
- 96 Lau CI, Wang HC & Hsu WC. Hypoglycemic encephalopathy as the initial presentation of hepatic tumor: a case report. *Neurologist* 2010 **16** 206–207. (doi:10.1097/NRL.0b013e3181a6ec56)
- 97 Habra MA, Nunez R, Chuang H, Ayala-Ramirez M, Rich T, Kyle K & Jimenez C. Fatal hypoglycemia in malignant pheochromocytoma: direct glucose consumption as suggested by (18)F-2-fluoro-2-deoxy-D-glucose positron emission tomography/computed tomography imaging. *Endocrine* 2010 **37** 209–212. (doi:10.1007/s12020-009-9300-1)
- 98 Di Comite G, Dagna L, Piatti PM, Monti LD, Tantardini F & Praderio L. Hypoglycaemia and lactic acidosis in a MALT non Hodgkin's lymphoma. *Leukemia & Lymphoma* 2002 **43** 1341–1342.
- 99 Glasheen JJ & Sorensen MD. Burkitt's lymphoma presenting with lactic acidosis and hypoglycemia – a case presentation. *Leukemia & Lymphoma* 2005 **46** 281–283. (doi:10.1080/10428190400016723)
- 100 Vieweg WV, Reitz RE & Weinstein RL. Addison's disease secondary to metastatic carcinoma: an example of adrenocortical and adrenomedullary insufficiency. *Cancer* 1973 **31** 1240–1243.

Received 10 December 2013

Revised version received 19 January 2014

Accepted 23 January 2014